

# PEDIATRICS®

OFFICIAL JOURNAL OF THE AMERICAN ACADEMY OF PEDIATRICS

## **Frenulotomy for Breastfeeding Infants With Ankyloglossia: Effect on Milk Removal and Sucking Mechanism as Imaged by Ultrasound**

Donna T. Geddes, Diana B. Langton, Ian Gollow, Lorili A. Jacobs, Peter E. Hartmann  
and Karen Simmer

*Pediatrics* 2008;122:e188; originally published online June 23, 2008;  
DOI: 10.1542/peds.2007-2553

The online version of this article, along with updated information and services, is  
located on the World Wide Web at:

<http://pediatrics.aappublications.org/content/122/1/e188.full.html>

PEDIATRICS is the official journal of the American Academy of Pediatrics. A monthly publication, it has been published continuously since 1948. PEDIATRICS is owned, published, and trademarked by the American Academy of Pediatrics, 141 Northwest Point Boulevard, Elk Grove Village, Illinois, 60007. Copyright © 2008 by the American Academy of Pediatrics. All rights reserved. Print ISSN: 0031-4005. Online ISSN: 1098-4275.

American Academy of Pediatrics

DEDICATED TO THE HEALTH OF ALL CHILDREN™



# Frenulotomy for Breastfeeding Infants With Ankyloglossia: Effect on Milk Removal and Sucking Mechanism as Imaged by Ultrasound

Donna T. Geddes, PhD<sup>a</sup>, Diana B. Langton, BSc, IBCLC<sup>b</sup>, Ian Gollow, MBBS, FRACS<sup>c</sup>, Lorili A. Jacobs, MSc<sup>d</sup>, Peter E. Hartmann, PhD<sup>a</sup>, Karen Simmer, MBBS, FRCPH, PhD<sup>e</sup>

<sup>a</sup>School of Biomedical, Biomolecular, and Chemical Sciences, University of Western Australia, Perth, Australia; <sup>b</sup>Breastfeeding Centre, King Edward Memorial Hospital, Subiaco, Western Australia, Perth, Australia; <sup>c</sup>School of Pediatrics and Child Health, Princess Margaret Hospital, Perth, Australia <sup>d</sup>Ultrasound Department and <sup>e</sup>Neonatal Clinical Care Unit, King Edward Memorial Hospital, Perth, Australia

The authors have indicated they have no financial relationships relevant to this article to disclose.

## What's Known on This Subject

Frenulotomy seems to improve feeding for infants experiencing difficulties; however, it remains controversial, mainly because a proportion of infants with ankyloglossia are able to feed successfully.

## What This Study Adds

This study clarifies that frenulotomy of infants with ankyloglossia changes the tongue movement of breastfeeding infants and improves feeding evidenced by increased milk-transfer and feeding efficiency and decreased maternal perception of pain.

## ABSTRACT

**OBJECTIVE.** There is evidence that infants with ankyloglossia can experience breastfeeding difficulties including poor attachment to the breast, suboptimal weight gain, and maternal nipple pain, which may lead to early weaning of the infant. No studies have investigated the cause of these breastfeeding difficulties. The objective of this study was to determine the effectiveness of frenulotomy in infants experiencing persistent breastfeeding difficulties despite professional assistance by measuring changes in milk transfer and tongue movement during breastfeeding before and after frenulotomy.

**PATIENTS AND METHODS.** Twenty-four mother-infant dyads (infant age:  $33 \pm 28$  days) that were experiencing persistent breastfeeding difficulties despite receiving professional advice were recruited. Submental ultrasound scans (Acuson XP10) of the oral cavity were performed both before and  $\geq 7$  days after frenulotomy. Milk transfer, pain, and LATCH (latch, audible swallowing, type of nipple, comfort, and hold) scores were recorded before and after frenulotomy. Infant milk intake was measured by using the test-weigh method.

**RESULTS.** For all of the infants, milk intake, milk-transfer rate, LATCH score, and maternal pain scores improved significantly postfrenulotomy. Two groups of infants were identified on ultrasound. One group compressed the tip of the nipple, and the other compressed the base of the nipple with the tongue. These features either resolved or lessened in all except 1 infant after frenulotomy.

**CONCLUSIONS.** Infants with ankyloglossia experiencing persistent breastfeeding difficulties showed less compression of the nipple by the tongue postfrenulotomy, which was associated with improved breastfeeding defined as better attachment, increased milk transfer, and less maternal pain. In the assessment of breastfeeding difficulties, ankyloglossia should be considered as a potential cause. *Pediatrics* 2008;122:e188–e194

[www.pediatrics.org/cgi/doi/10.1542/peds.2007-2553](http://www.pediatrics.org/cgi/doi/10.1542/peds.2007-2553)

doi:10.1542/peds.2007-2553

### Key Words

ankyloglossia, tongue tie, frenulotomy, breastfeeding, ultrasound, feeding, lactation

### Abbreviations

HSPJ—hard/soft palate junction  
NHSPJD—nipple to the hard/soft palate junction distance  
LATCH—latch, audible swallowing, type of nipple, comfort, and hold

Accepted for publication Jan 18, 2007

Address correspondence to Donna Geddes, PhD, University of Western Australia, M310, 35 Sirling Hwy, Crawley, Perth, West Australia 6009, Australia. E-mail: donna.geddes@uwa.edu.au

PEDIATRICS (ISSN Numbers: Print, 0031-4005; Online, 1098-4275). Copyright © 2008 by the American Academy of Pediatrics

**P**ARTIAL ANKYLOGLOSSIA IS defined as a short lingual frenulum that results in restricted range of tongue movement such as limitation of the forward protrusion of the tongue and/or lateral mobility of the tongue.<sup>1</sup> The reported incidence of ankyloglossia ranges from 3.2% to 10.7%.<sup>2-4</sup> There is evidence associating this condition with feeding, swallowing, and speech difficulties.<sup>3-6</sup> In particular, between 12.8% and 44% of infants reportedly experience breastfeeding problems,<sup>3,4</sup> yet the clinical significance of ankyloglossia still remains controversial.<sup>6</sup>

With heightened awareness of the risks to infants not receiving breast milk,<sup>7-9</sup> breastfeeding rates have increased since the early 1970s. However, despite increased initiation, the duration of breastfeeding is often short, with only approximately half of Australian and West Australian women still exclusively breastfeeding at 3 months<sup>10</sup> and  $< 1\%$  at 6 months.<sup>10,11</sup> The main causes given for early weaning of the infant are either real or perceived insufficient milk supply and nipple pain. Both of these symptoms have been associated with ankyloglossia, and, therefore, ankyloglossia should be considered as a contributing factor when assessing women with breastfeeding difficulties.

Treatment of ankyloglossia is frenulotomy to release the lingual frenulum. It is a relatively simple procedure with few adverse effects and minimal aftercare.<sup>1,12</sup> Although studies have assessed the immediate clinical effects of frenulotomy, none have examined sucking dynamics of these infants. The aim of this study was to determine the changes in milk production, breastfeeding characteristics (milk-transfer rates, maternal pain, positioning, and attachment), and the sucking dynamics of infants with ankyloglossia before and after frenulotomy.

## METHODS

### Participants

Health professionals referred 24 mothers of healthy, term infants experiencing breastfeeding difficulties from either the King Edward Memorial Hospital or private health centers. Mothers were referred on the basis that they had received lactation advice and follow-up, yet breastfeeding difficulties had not resolved. Mothers supplied written, informed consent to participate in the study, which was approved by the human research ethics committee of King Edward Memorial Hospital.

### Protocol

#### *Prefrenulotomy*

##### *Clinical Assessment*

The mothers and infants participated in the study at the Breastfeeding Centre of Western Australia (King Edward Memorial Hospital). Eight women were able to perform 24-hour milk productions before frenulotomy. Twenty-four-hour milk production was determined for each breast by the test-weigh method. Briefly the infants were weighed by using a Medela Electronic Infant Weigh Scale (Medela AG, Barr, Switzerland) before and after breastfeeding, and milk intake was calculated by subtracting the initial weight of the infant from the final weight of the infant. This procedure was conducted for a 24- to 28-hour period and corrected to 24-hour production.<sup>13</sup> The remaining mothers in the study did not complete milk productions, because they were anxious that a delay to frenulotomy would further exacerbate their breastfeeding problems.

On the first day of the study, the lactation consultant informed the mother about the study and obtained written consent. For the study ultrasound, LATCH, pain, and milk transfer were assessed during a breastfeed from 1 breast. During the feed, the lactation consultant assessed the breastfeed by using the LATCH system, and the ultrasonographer scanned the infant oral cavity. LATCH is a numerical scoring system addressing 5 key components of breastfeeding: latch, audible swallowing, type of nipple, comfort, and hold (positioning). The infant scores 0, 1, or 2, with a maximum score of 10. It is designed as a systematic assessment of breastfeeding that can identify areas of intervention necessary to facilitate successful breastfeeding.<sup>14</sup> The mothers assessed pain during the breastfeed by using a pain score of 0 to 10, with 10 representing the most severe pain. Milk intake was measured for the breastfeed by test weighing.<sup>15</sup>

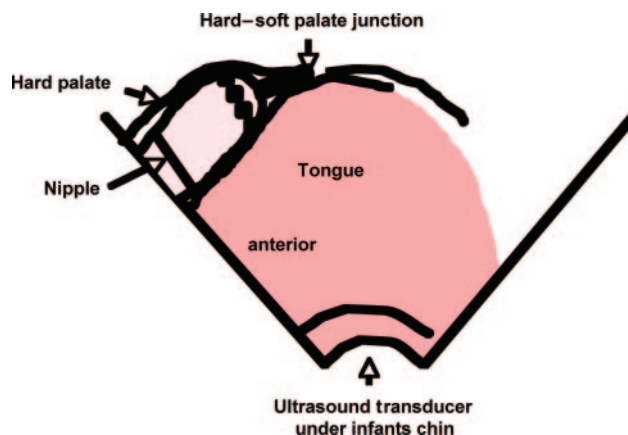


FIGURE 1

Schematic diagram of the submental sagittal view of infant oral cavity with the tongue up in apposition with the palate. Measurements are made from the tip of the nipple to the NHSPJD. The distortion of the nipple is calculated by dividing nipple diameter at the tip of the nipple (dotted line) by nipple diameter at the base of the nipple (solid line) multiplied by 100.

The same lactation consultant assessed the mother and infant for the prefrenulotomy and postfrenulotomy breastfeeds. Two ultrasonographers performed the scans of the breastfeeds. One ultrasonographer performed the first 7 scans but was unable to continue the study. The same ultrasonographer performed both the prefrenulotomy and postfrenulotomy scans.

##### *Ultrasound Imaging*

Submental scans of the midline of the infant's oral cavity were performed<sup>16-19</sup> using an Acuson XP10 (Siemens, Mountain View, CA) with an endocavity convex transducer (7 MHz). The transducer was rotated until the longest image of the nipple was obtained and a clear view of the hard/soft palate junction (HSPJ) was achieved (Fig 1). Average setting values for the Acuson XP10 were gain of 5 dB, dynamic range of 57 dB, and single focus adjusted to the level of the nipple. Additional adjustments were made to the gain, dynamic range, and time gain compensation to optimize the image during scanning. All of the ultrasound scans began when the infant attached to the breast and ended when the infant finished feeding. The scan was videotaped for later analysis. Parker Ultrasonic Gel (Fairfield, New NJ) was used for the scans.

### Frenulotomy Procedure

After the surgeon counseled the parents with regard to the risks and benefits of the procedure, written informed consent was obtained. The infant was then wrapped to immobilize the arms and placed supine on an examining table. The lactation consultant held the infant's head firmly to avoid movement. The pediatric surgeon then lifted the tongue with his fingers to examine the frenulum and ensure that it was both thin and devoid of large blood vessels. Using sterile iris scissors, a small cut was made at the anterior portion of the frenulum extending just past the genioglossus muscle. The infant was then encouraged to breastfeed.

### Analysis of Ultrasound Images

The following measurements were made for 5 suck cycles during milk flow as identified on ultrasound imaging<sup>19</sup>: nipple to the HSPJ distance (NHSPJD) and degree of nipple distortion (nipple diameter at the tip of the nipple divided by nipple diameter at the base of the nipple multiplied by 100; Fig 1) were calculated. The measurements were made at 2 points in each suck cycle. The first point was when the tongue was in its uppermost position in apposition with the hard palate (tongue up). The second was when the tongue was in its lowermost position and milk flow was visible<sup>19</sup> (tongue down). The mean range of movement of the nipple was the mean of the difference of the NHSPJD in the tongue-up and tongue-down positions for the 5 suck cycles. Measurements were made with the calibrated software program Meander 1.5 (2003–2006, Peacock Media, Actus Trading Ltd, Calgary, AB, Canada).

### Postfrenulotomy

Infants were clinically and objectively assessed with LATCH, maternal pain scores, and ultrasound scans recorded  $\geq 7$  days after frenulotomy as described for the prefrenulotomy investigations.

### RESULTS

The 24 infants studied were  $33 \pm 28$  days (range: 4–131 days) of age at the day of presentation. Two of the mothers were not in established lactation (day 4 and day 8), and 1 of these mothers reported 10 of 10 on the pain score. The infants were studied again 7 to 29 days ( $13 \pm 6$  days) after frenulotomy. Infant age postfrenulotomy was  $45 \pm 30$  days (range: 22–150 days). Eight of the mothers recorded 24-hour milk production before frenulotomy (infant age:  $35 \pm 18$  days [range: 18–71 days]), and 6 mothers completed milk productions 6 to 12 days after frenulotomy ( $8 \pm 2$  days).

### Breastfeeding Characteristics

The details of 24-hour milk productions for the 8 mothers prefrenulotomy and 6 mothers postfrenulotomy are given in Table 1. Note that 6 mothers had milk productions  $< 500$  g. One mother had a milk production of 1034 g before frenulotomy and 1094 g after frenulotomy. Before frenulotomy ( $n = 6$ ), the mean milk productions from the right and left breasts were  $259 \pm 239$  and  $199 \pm 93$  g, respectively, and total milk production was  $455 \pm 323$  g. After frenulotomy, the mean milk production from the right breast increased significantly to  $345 \pm 254$  g ( $P = .042$ ), and the milk production from the left breast increased to  $265 \pm 65$  g ( $P = .08$ ). In addition, total milk production after frenulotomy increased significantly to  $615 \pm 289$  g ( $P = .035$ ).

There were no complications of frenulotomy reported. Most infants cried briefly after the frenulotomy; however, they showed no signs of distress after a breastfeed immediately after the procedure. Data for assessment of the monitored breastfeed before and after frenulotomy ( $\geq 7$  days after the procedure) are detailed in Table 2. Milk intake, milk transfer, and LATCH score

TABLE 1 Twenty-Four-Hour Milk Production, as Measured by the Test-Weigh Method, Prefrenulotomy and Postfrenulotomy

Mother	Prefrenulotomy						Postfrenulotomy						
	Right Breast		Left Breast		Total Milk Production		Right Breast		Left Breast		Total Milk Production		
	Milk Production, g	Feed Volume, g	Length of Feed, min	Milk Production, g	Feed Volume, g	Length of Feed, min	Milk Production, g	Feed Volume, g	Length of Feed, min	Milk Production, g	Feed Volume, g	Length of Feed, min	Total Milk Production
1	64	13	23	94	20	18	232	42	17	288	51	18	521
2	332	42	16	175	35	21	360	58	19	265	42	16	624
3	705	96	20	281	41	16	818	78	18	277	38	19	1094
4	207	31	8	306	40	10	249	17	6	300	27	8	549
5	219	32	17	156	23	15	NA	NA	NA	NA	NA	NA	NA
6	167	28	26	248	47	27	343	50	16	322	67	21	699
7	100	14	18	68	8	17	NA	NA	NA	NA	NA	NA	NA
8	76	11	14	92	17	20	65	14	18	139	30	18	204
Mean	234	33	18	177	29	18	345	43	16	265	43	17	615

NA indicates not applicable.

**TABLE 2** Characteristics of the Breastfeed Infants Monitored Before and  $\geq 7$  Days After Frenulotomy

Variable	Prefrenulotomy	Postfrenulotomy
Milk intake	50.5 $\pm$ 29.1 g	69.1 $\pm$ 31.9 g <sup>a</sup>
Milk transfer, mL/min	5.6 $\pm$ 3.0 g	10.5 $\pm$ 5.5 g <sup>a</sup>
LATCH score	7.9 $\pm$ 1.4	9.4 $\pm$ 0.8 <sup>b</sup>
Pain score	3.6 $\pm$ 3.0	0.5 $\pm$ 1.2 <sup>b</sup>
Nipple shield, n/N	4/24	1/24

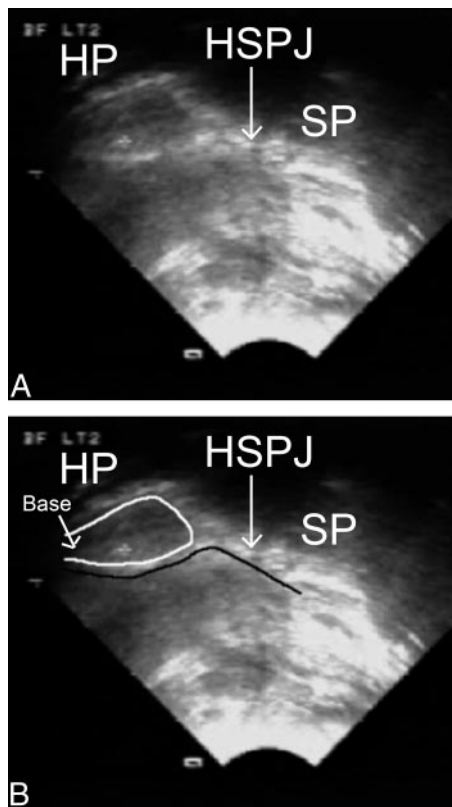
<sup>a</sup>  $P < .01$ .

<sup>b</sup>  $P < .05$ .

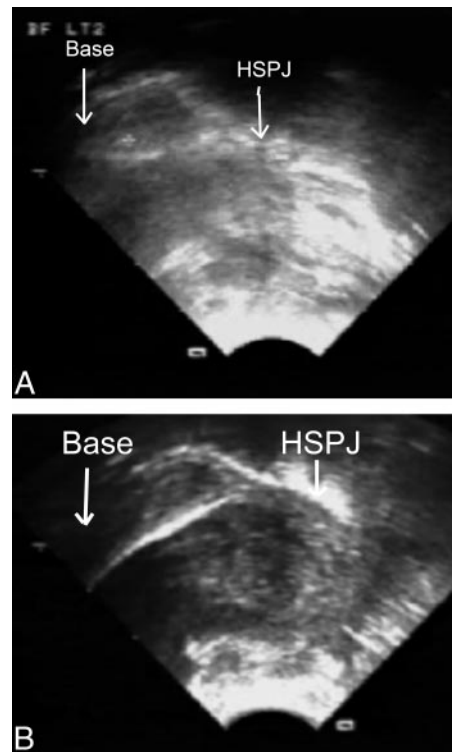
were all significantly increased, and the mother's pain score was significantly reduced postfrenulotomy. There was no correlation between the mother's perception of pain and her LATCH score. The duration of breastfeeding (any breastfeeding) after frenulotomy was 11.3  $\pm$  5.2 months (range: 5–24 months;  $n = 16$ ).

### Ultrasound

Observational analysis of the ultrasound scans revealed 2 distinct patterns of sucking by the infants before frenulotomy. One group of infants (11 of 24 [46%]) placed the nipple close to the HSPJ and pinched the base of the nipple (base compression group, Fig 2). This resolved in all but 1 infant after frenulotomy (Fig 3). The second



**FIGURE 2**  
A, Ultrasound image of the oral cavity of a breastfeeding infant with ankyloglossia prefrenulotomy. The tongue is up in contact with the palate. The hard palate (HP), soft palate (SP), and HSPJ are marked. B, Note the compression of the base of the nipple (outlined in white). Compression of the nipple is caused by upward movement of the distal portion of the tongue (outlined in black).



**FIGURE 3**

A, Ultrasound image of an infant with ankyloglossia prefrenulotomy. The base of the nipple is compressed. B, Postfrenulotomy, the base of the nipple is compressed to a lesser degree compared with prefrenulotomy.

group (9 of 24 [37%]) placed the nipple further away from the HSPJ, and the posterior tongue seemed to hump compressing the tip of the nipple to a point (point compression group, Fig 4). These features either resolved or lessened after frenulotomy (Fig 5). Three infants (13%) did not seem to compress the nipple; however, the distance from the HSPJ was reduced after frenulotomy. In 1 infant (4%), the ultrasound scan displayed no untoward features both before and after frenulotomy, although the mother rated 7 for LATCH and 3 for pain score prefrenulotomy and 9 for LATCH and 0 for pain score postfrenulotomy. This mother also had a good 24-hour milk production of 1034 g before frenulotomy. Objective analysis of the ultrasound images is shown in Tables 3 and 4. There was no difference in either the pain or latch score for the 2 groups.

### Statistical Analysis

Student's paired  $t$  tests were used to determine differences between measurements before and after frenulotomy. Two-way analysis of variance was performed to determine differences between groups of mothers (point compression group and base compression group as defined by ultrasound) both before and after frenulotomy. Correlation coefficients were calculated by using the statistical software package SPSS for Windows Student Version 14.0.0 (SPSS Inc, Chicago, IL).  $P$  values of  $< .05$  were taken to be significant.



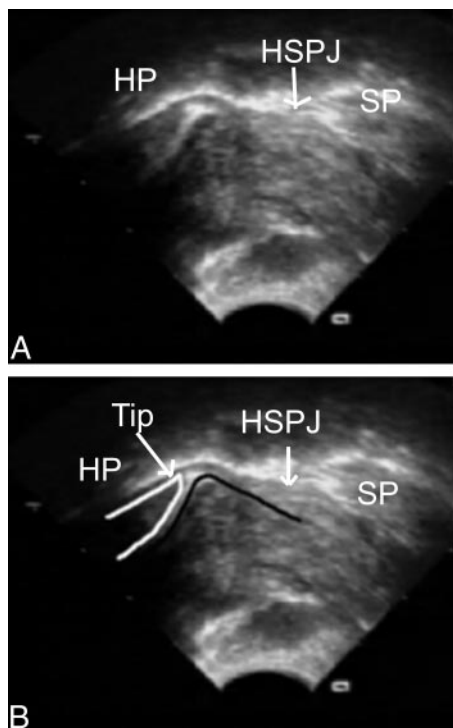


FIGURE 4

A, Ultrasound image of the oral cavity of a breastfeeding infant with ankyloglossia pre-frenulotomy. The tongue is up in contact with the palate. The hard palate (HP), soft palate (SP), and HSPJ are marked. B, Note the compression of the tip of the nipple (outlined in white). The tongue appears "humped" distal to the nipple (outlined in black).

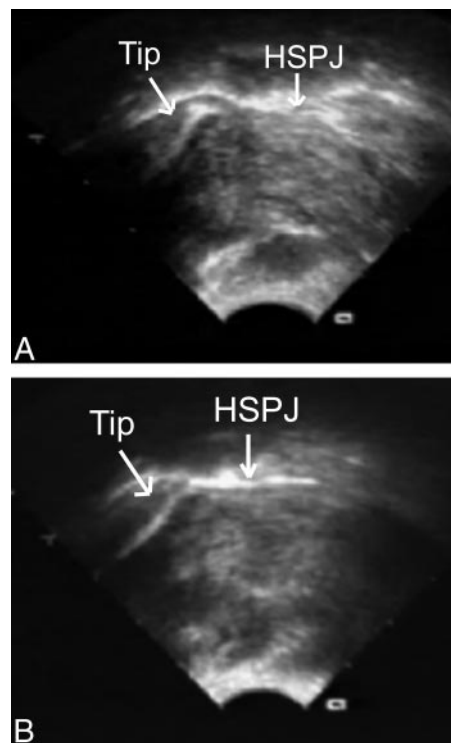


FIGURE 5

A, Ultrasound image of an infant with ankyloglossia pre-frenulotomy. The tip of the nipple is compressed. B, Postfrenulotomy the tip of the nipple is compressed to a lesser degree compared with pre-frenulotomy.

## DISCUSSION

### Breastfeeding Characteristics

The initial design of this study included the measurement of 24-hour milk production for mothers and infants with ankyloglossia before and after frenulotomy to determine whether the mother had a low milk supply before frenulotomy and whether correction of ankyloglossia would result in an increase in milk production. This protocol restricted the recruitment of mothers and infants, with many mothers declining to participate in the study because they felt that the milk production assessment was an unnecessary delay to their infant's treatment. Only 8 mothers completed milk productions before frenulotomy, and 6 mothers completed milk productions postfrenulotomy (Table 1). Despite the small number of mothers in this sample, this is the first milk production data published for infants with ankyloglossia. The 24-hour milk productions increased significantly after frenulotomy by 36 to 362 g. It is of concern that total milk production was compromised by ankyloglossia in 6 of the 8 women (reference range: 478–1356 g<sup>13</sup>), with 1 woman at the lower end of the reference range (513 g). These results lend weight to the clinical observations of poor weight gain because of assumed decreased milk supply or milk transfer in women experiencing difficulties breastfeeding infants with ankyloglossia. Therefore, identification of ankyloglossia at birth and close monitoring of feeding may detect milk supply problems earlier. The mother who had a normal milk production of 1034 g (mother 3; Table 1) recorded a

LATCH score of 9 and a pain score of 0. In addition, the ultrasound imaging during breastfeeding showed normal tongue movements and nipple positioning both before and after frenulotomy despite a moderate-to-severe clinical grading of ankyloglossia by the pediatric surgeon. Referral of this mother for feeding problems was clearly inappropriate. Another point of note is that, whereas the duration of the breastfeeds did not change dramatically, the mean feed volume over the 24-hour period generally increased postfrenulotomy (increased mean feed volume for both breasts in 6 women and 1 breast in 2 women), inferring that infants were able to remove more milk from the breast after the release of the frenulum. Additional investigation of milk production in mothers with infants with ankyloglossia is required.

A clinical assessment tool has been developed to assess the severity of ankyloglossia and, hence, aid in the recommendation of infants for frenulotomy (the Hazelbaker Assessment Tool for Lingual Frenulum Function<sup>20</sup>). However, not all of the function items on the tool have good interrater reliability.<sup>21,22</sup> Amir et al<sup>21</sup> found that the first 3 function items were reliable indicators of severity of ankyloglossia. These items assess the mobility of the tongue and are forward extension, lateral movement (sideways movement of the tongue as opposed to cupping), and elevation of the tongue. More recently, however, a simple tool has been designed (the Frenotomy Decision Rule for Breastfeeding Infants) that makes a diagnosis of suitability for frenulotomy on key signs such as maternal pain and/or trauma, poor infant

weight gain, and visible short lingual frenulum with impaired superior, forward, or cupping movement of the tongue.<sup>23</sup> This approach is in accordance with Hogan et al,<sup>2</sup> who found no relationship between frenulum length and breastfeeding difficulties and, therefore, concluded that severity of breastfeeding difficulties should be the primary method of determining whether frenulotomy should be performed. The LATCH tool was used to assess the breastfeed in this study, and although it is not designed specifically for infants with ankyloglossia, it is a validated tool for identifying mothers at risk of early weaning and has been used in a recent study of infants who underwent frenulotomy.<sup>23</sup> The infants in this study showed a significant improvement in their LATCH score (Table 2) as they did in the study by Srinivasan et al,<sup>23</sup> providing evidence that frenulotomy can improve the positioning and attachment of the infant to the breast.

Nipple pain is a common symptom observed in breastfeeding mothers of infants with ankyloglossia.<sup>2-4,23</sup> Importantly, breast and nipple pain are the second most common reason to perceived inadequate milk supply for weaning reported by mothers in the first 3 weeks postpartum.<sup>10,24</sup> Early weaning not only impacts on infant health but can also have long-term psychological effects for the mother.<sup>25</sup> Often the pain experienced by the mother is so intense that she is unable to feed, and it is often further complicated by nipple trauma and may lead to subsequent infection and/or mastitis.<sup>26</sup> In addition, pain experienced by the mother during breastfeeding has been shown to reduce milk transfer to the infant presumably via interruption of the milk ejection reflex.<sup>27</sup> The mothers in this study reported lower pain levels associated with breastfeeding post-frenulotomy (Table 2), which is in agreement with the randomized, prospective study conducted by Dollberg et al.<sup>28</sup> The intensity of pain experienced by the mothers was not related to the LATCH score; thus, the importance of pain as a contributing factor to weaning may be overlooked when using this tool.

Infants in this study took more milk more quickly on the study day postfrenulotomy (Table 2). The increase in milk volume and rate of milk transfer for the infants post-frenulotomy more closely approximated that documented for successful breastfeeding infants.<sup>13</sup> It is likely that increased effectiveness and efficiency of feeding would increase the probability of a successful lactation. Indeed, both 24-hour milk production data and durations of breastfeeding support this assumption (Table 1). The duration of breastfeeding for mothers and infants in this study is high, with only 1 mother not continuing to breastfeed after 5 months. Other studies have shown 64% and 60% of mothers breastfed for >3 months after frenulotomy.<sup>2,12</sup> Nipple shields were used to facilitate breastfeeding in 3 of the infants before frenulotomy. This intervention was used because the mother experienced nipple pain during feeding. The 2 mothers who did not require a nipple shield postfrenulotomy had a reduction in nipple pain from 3 of 10 and 4 had a reduction of 10 to 0.

### Ultrasound Imaging

Ultrasound imaging has been used to observe tongue movement of normal term infants during breastfeeding.

Most recently, Geddes et al<sup>19</sup> have shown that the intraoral vacuum applied by the established breastfeeding infant corresponds with the downward movement of the tongue and milk flow. As the tongue moves up and down, there is minimal distortion of the nipple, thus, a marked peristaltic movement was not shown (Fig 1). Minimal distortion of the nipple during successful breastfeeding, as observed by ultrasound, corresponds well with the absence of misshapen nipples observed postfeeding by lactation professionals.

In this study, it was possible by observing the ultrasound images to clearly identify 2 different sucking dynamics of the infants with ankyloglossia. In the first group (point compression group) the infant sucking action pinched the tip of the nipple, and the nipple was placed a large distance from the hard soft palate junction (HSPJ; Fig 4 and Table 3). The second group (base compression group) pinched the nipple at the base, and the nipple was in close proximity to the HSPJ (Fig 2 and Table 3). The measurements made of the ultrasound images confirm these observations. The distance of the nipple from the HSPJ in the point compression group is double that of the base compression group both when the tongue is up and down pre-frenulotomy (12.8 vs 6.3 mm and 8.3 vs 4 mm). Similarly, the nipple diameter was significantly reduced when the tongue was in the up and down positions in the point compression group pre-frenulotomy, whereas in the base compression group the reduction in the diameter of the nipple at the base was more marked when the tongue was in the down position (Table 4). Two different clinical presentations of breastfeeding infants with ankyloglossia have also been identified. One group of infants was observed to either "bite" or latch strongly to the breast, and the other group had difficulty maintaining a seal to the breast. Both groups may cause nipple trauma. It has been assumed that the tight frenulum causes the tongue to move back toward the floor of the mouth quickly, thus producing an ineffective seal to the breast or inducing the infant to grasp the breast more firmly to suckle.<sup>29</sup> It is postulated that the 2 groups identified by ultrasound imaging are related to these clinical groups. The group that pinched the base of the nipple may represent the clinical group of infants who grasp the breast strongly to suck (Fig 2). However, the group that showed compression of the tip of the nipple and a longer NHSPJ distance may represent the infants who are unable to maintain a seal to the breast (Fig 4). To confirm this hypothesis, a study is currently in progress to investigate the relationship of nipple distortion imaged by ultrasound and the intraoral vacuum applied by the infant.

Release of the frenulum altered infant tongue movement as imaged by ultrasound during breastfeeding (Figs 3 and 5). The point compression group displayed a significant decrease in NHSPJ distance and a reduction in compression of the nipple when the tongue was in the up position. The base compression group did not show a change in the NHSPJ distance but had a significant reduction in compression at the base of the nipple when the tongue was in both the up and down positions. Furthermore, postfrenulotomy, there was no difference

in either the NHSPJ distance between the 2 groups or nipple compression when the tongue was up. Although this study did not include a control group, NHSPJ distances after frenulotomy (tongue up: 7.1 mm; tongue down: 4.5 mm) closely approximate those of a normal group scanned by Geddes et al<sup>19</sup> (tongue up: 6.9 mm; tongue down: 5.2 mm). Jacobs et al<sup>18</sup> quoted median NHSPJ distances of 5 mm for infants at 1 week and 4 weeks of life; however, this was calculated from multiple measurements during the suck cycle. Jacobs et al<sup>18</sup> also calculated nipple movement as the maximum NHSPJ distance minus the minimum NHSPJ distance for several suck cycles (4 mm). This measurement is likely to overestimate nipple movement, because each suck cycle was not measured as a separate event, hence the discrepancy with our results (2.6 mm). There was still some persistence of nipple compression at the tip of the nipple in the first group postfrenulotomy compared with the second group. To summarize the ultrasound imaging results: frenulotomy in infants with ankyloglossia changed tongue movement during breastfeeding and reduced the degree of nipple distortion.

## CONCLUSIONS

Ultrasound imaging of infants with ankyloglossia, who were experiencing persistent feeding problems, identified 2 different tongue movements during breastfeeding. The infants compressed either the base or the tip of the nipple. In infants who compressed the tip of the nipple, the nipple was further from the HSPJ than those who compressed the base of the nipple. These features resolved after frenulotomy, along with improved milk intake, milk-transfer rates, attachment to the breast, and maternal pain. In conclusion, this study provides evidence in support of frenulotomy for infants experiencing persistent breastfeeding difficulties despite professional advice and demonstrates that ultrasound imaging may successfully identify sucking anomalies in infants with ankyloglossia. Therefore, in the assessment of breastfeeding difficulties, ankyloglossia should be considered as a contributing factor.

## ACKNOWLEDGMENT

Medela AG provided the PhD scholarship for Dr Geddes at the time that the study was conducted.

## REFERENCES

- Academy of Breastfeeding Medicine. ABM clinical protocol #11: guidelines for the evaluation and management of neonatal ankyloglossia and its complications in the breastfeeding dyad. 2004. Available at: [www.bfmed.org/ace-files/protocol/ankyloglossiafinal11.pdf](http://www.bfmed.org/ace-files/protocol/ankyloglossiafinal11.pdf). Accessed May 7, 2008
- Hogan M, Westcott C, Griffiths M. Randomised controlled division of tongue tie infants with breastfeeding problems. *J Paediatr Child Health*. 2005;41(5-6):246-250
- Ballard JL, Auer CE, Khoury JC. Ankyloglossia: assessment, incidence, and effect of frenuloplasty on the breastfeeding dyad. *Pediatrics*. 2002;110(5). Available at: [www.pediatrics.org/cgi/content/full/110/5/e63](http://www.pediatrics.org/cgi/content/full/110/5/e63)
- Messner AH, Lalakea MH, Aby J, MacMahon J, Bair E. Ankyloglossia incidence and associated feeding difficulties. *Arch Otolaryngol Head Neck Surg*. 2000;126(1):36-39
- Lalakea ML, Messner AH. Ankyloglossia: the adolescent and adult perspective. *Otolaryngol Head Neck Surg*. 2003;128(5):746-752
- Messner AH, Lalakea MH. Ankyloglossia: controversies in management. *Int J Pediatr Otorhinolaryngol*. 2000;54(2-3):123-131
- Cunningham AS, Jelliffe DB, Jelliffe EF. Breastfeeding and health in the 1980s: a global epidemiological review. *J Pediatr*. 1991;118(5):659-666
- Singhal A, Cole TJ, Lucas A. Early nutrition in pre-term infants and later blood pressure: 2 cohorts after randomised trials. *Lancet*. 2001;357(9254):431-419
- American Academy of Pediatrics, Working Group on Breastfeeding. Breastfeeding and the use of human milk. *Pediatrics*. 1997;100(6):1035-1039
- Win NN, Binns CW, Zhao Y, Scott JA, Oddy WH. Breastfeeding duration in mothers who express breast milk: a cohort study. *Int Breastfeed J*. 2006;1:28
- Scott JA, Binns CW, Oddy WH, Graham KI. Predictors of breastfeeding duration: evidence from a cohort study. *Pediatrics*. 2006;117(4). Available at: [www.pediatrics.org/cgi/content/full/117/4/e646](http://www.pediatrics.org/cgi/content/full/117/4/e646)
- Griffiths DM. Do tongue ties affect breastfeeding? *J Hum Lact*. 2004;20(4):409-414
- Kent JC, Mitoulas LR, Cregan MD, Ramsay DT, Doherty DA, Hartmann PE. Volume and frequency of breastfeeds and fat content of breastmilk throughout the day. *Pediatrics*. 2006;117(3). Available at: [www.pediatrics.org/cgi/content/full/117/3/e387](http://www.pediatrics.org/cgi/content/full/117/3/e387)
- Jensen D, Wallace S, Kelsay P. LATCH: a breastfeeding charting system and documentation tool. *J Obstet Gynecol Neonatal Nurs*. 1994;23(1):27-32
- Arthur PG, Hartmann PE, Smith M. Measurement of milk intake of breastfed infants. *J Pediatr Gastroenterol Nutr*. 1987;6(5):758-763
- Woolridge MW. The anatomy of infant sucking. *Midwifery*. 1986;2(4):164-171
- Smith WL, Erenberg A, Nowak A. Imaging evaluation of the human nipple during breast-feeding. *Am J Dis Child*. 1988;142(1):76-78
- Jacobs LA, Dickinson JE, Hart DP, Doherty DA, Faulkner SJ. Normal nipple position in term infants measured on breastfeeding ultrasound. *J Hum Lact*. 2007;23(1):52-59
- Geddes DT, Kent JC, Mitoulas LR, Hartmann PE. Tongue movement and intra-oral vacuum in breastfeeding infants. *Early Hum Dev*. 2008; In press
- Hazelbaker AK. *The Assessment Tool for Lingual Frenulum Function (ATLFF): Use in a Lactation Consultant Private Practice*. Los Angeles, CA: Pacific Oaks College; 1993
- Amir LH, James JP, Donath SM. Reliability of the hazelbaker assessment tool for lingual frenulum function. *Int Breastfeed J*. 2006;1(1):3
- Madlon-Kay DJ, Ricke LA, Baker NJ, Defor TA. Case series of 148 tongue-tied newborn babies evaluated with the assessment tool for lingual frenulum function. *Midwifery*. 2007; In press
- Srinivasan A, Dobrich C, Mitnick H, Feldman P. Ankyloglossia in breastfeeding infants: the effect of frenotomy on maternal nipple pain and latch. *Breastfeed Med*. 2006;1(4):216-224
- Thomassen P, Johansson VA, Wassberg C, Petrini B. Breast-feeding, pain and infection. *Gynecol Obstet Invest*. 1998;46(2):73-74
- Mozingo JN, Davis MW, Droppleman PG, Merideth A. "It wasn't working": women's experiences with short-term breastfeeding. *MCN Am J Matern Child Nurs*. 2000;25(3):120-126
- Wilson-Clay B, Hoover K. *The Breastfeeding Atlas*. 3rd ed. Manchaca, TX: LactNews Press; 2005
- Newton M, Newton N. The let-down reflex in human lactation. *J Pediatrics*. 1948;33(6):698-704
- Dollberg S, Botzer E, Grunis E, Mimouni FB. Immediate nipple pain relief after frenotomy in breast-fed infants with ankyloglossia: a randomised, prospective study. *J Pediatr Surg*. 2006;41(9):1598-1600
- Marmet C, Marmet R. Neonatal frenotomy may be necessary to correct breastfeeding problems. *J Hum Lact*. 1990;6(3):117-121



## Frenulotomy for Breastfeeding Infants With Ankyloglossia: Effect on Milk Removal and Sucking Mechanism as Imaged by Ultrasound

Donna T. Geddes, Diana B. Langton, Ian Gollow, Lorili A. Jacobs, Peter E. Hartmann and Karen Simmer

*Pediatrics* 2008;122:e188; originally published online June 23, 2008;

DOI: 10.1542/peds.2007-2553

<b>Updated Information &amp; Services</b>	including high resolution figures, can be found at: <a href="http://pediatrics.aappublications.org/content/122/1/e188.full.html">http://pediatrics.aappublications.org/content/122/1/e188.full.html</a>
<b>Supplementary Material</b>	Supplementary material can be found at: <a href="http://pediatrics.aappublications.org/content/suppl/2008/07/07/peds.2007-2553.DC1.html">http://pediatrics.aappublications.org/content/suppl/2008/07/07/peds.2007-2553.DC1.html</a>
<b>References</b>	This article cites 21 articles, 5 of which can be accessed free at: <a href="http://pediatrics.aappublications.org/content/122/1/e188.full.html#ref-list-1">http://pediatrics.aappublications.org/content/122/1/e188.full.html#ref-list-1</a>
<b>Citations</b>	This article has been cited by 3 HighWire-hosted articles: <a href="http://pediatrics.aappublications.org/content/122/1/e188.full.html#related-urls">http://pediatrics.aappublications.org/content/122/1/e188.full.html#related-urls</a>
<b>Subspecialty Collections</b>	This article, along with others on similar topics, appears in the following collection(s): <b>Nutrition &amp; Metabolism</b> <a href="http://pediatrics.aappublications.org/cgi/collection/nutrition_and_metabolism">http://pediatrics.aappublications.org/cgi/collection/nutrition_and_metabolism</a>
<b>Permissions &amp; Licensing</b>	Information about reproducing this article in parts (figures, tables) or in its entirety can be found online at: <a href="http://pediatrics.aappublications.org/site/misc/Permissions.xhtml">http://pediatrics.aappublications.org/site/misc/Permissions.xhtml</a>
<b>Reprints</b>	Information about ordering reprints can be found online: <a href="http://pediatrics.aappublications.org/site/misc/reprints.xhtml">http://pediatrics.aappublications.org/site/misc/reprints.xhtml</a>

PEDIATRICS is the official journal of the American Academy of Pediatrics. A monthly publication, it has been published continuously since 1948. PEDIATRICS is owned, published, and trademarked by the American Academy of Pediatrics, 141 Northwest Point Boulevard, Elk Grove Village, Illinois, 60007. Copyright © 2008 by the American Academy of Pediatrics. All rights reserved. Print ISSN: 0031-4005. Online ISSN: 1098-4275.

American Academy of Pediatrics

DEDICATED TO THE HEALTH OF ALL CHILDREN™

